

## MANDIBULAR RECONSTRUCTION USING FREE VASCULARIZED ILIAC CREST GRAFTS AND DENTAL IMPLANTS

IULIU MOLDOVAN, MIHAI JUNCAR, CRISTIAN DINU,  
FLORIN ONISOR-GLIGOR, HORATIU ROTAR, SIMION BRAN,  
GRIGORE BACIUT

Department of Oral and Maxillofacial Surgery, Iuliu Hațieganu University of Medicine and Pharmacy, Cluj-Napoca, Romania

### Abstract

**Background and aim.** The mandible is frequently affected by tumor masses present in the oral cavity and is included in the tumor ablation procedure, with major functional and esthetic consequences for the patient. A method of high current interest in mandibular reconstruction is based on the use of free vascularized iliac crest grafts, followed by reconstruction using dental implants.

**Methods.** This study presents the case of four patients benefiting from this treatment method, and monitors the treatment stages and their clinical evolution after mandibular reconstruction and dental implant placement.

**Results.** The postoperative evolution of the patients was favorable, with the integration of the iliac crest grafts and dental implants. After prosthetic loading, the masticatory as well as the esthetic function of the patients was restored to a standard close to the initial one.

**Conclusions.** This mandibular reconstruction method proved to be effective, with a high degree of reliability and a significant improvement of the patients' quality of life.

**Keywords:** mandibular reconstruction, free vascularized flap, iliac crest graft, dental implants

### Background and aim

The treatment of malignant or benign tumors that affect the mandible involves in the majority of the cases the presence of a significant bone defect that may interfere with the patient's quality of life [1]. Due to the esthetic and functional importance of the mandible, its reconstruction is a major objective in the treatment of mandibular bone defects [2]. The aim of mandibular bone reconstruction is to obtain adequate bone amount for the placement of dental implants, for optimal muscle insertion, and to maintain the integrity of the inferior alveolar nerve where possible [3].

The use of iliac crest grafts for mandibular

reconstruction, after tumor ablation, is one of the oldest bone reconstruction methods [4]. The iliac crest was initially used as a non-vascularized graft. The advantage of this type of graft was the increased amount of bone tissue available for reconstruction, as well as the low cost of this procedure [2]. A disadvantage of this type of reconstruction is that it has no vascularization of its own, which has an unfavorable effect on the metabolism and volume stability of the bone graft [5,6]. In order to overcome this inconvenience, free vascularized bone grafts were introduced into medical practice, with better results in terms of volume stability as well as functional integration [5,6].

The aim of this study is to evaluate mandibular reconstruction using microsurgical iliac crest flaps, after tumor ablation.

Manuscript received: 14.04.2015

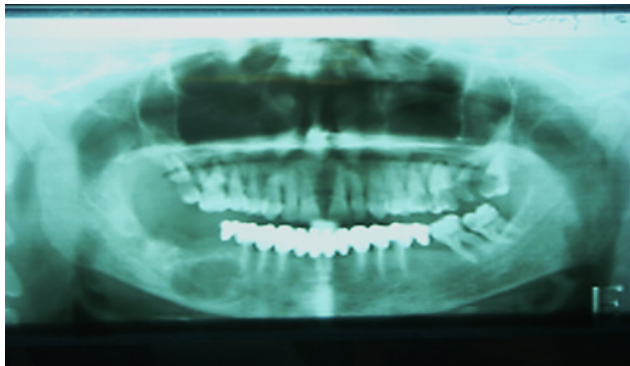
Received in revised form: 07.05.2015

Accepted: 13.05.2015

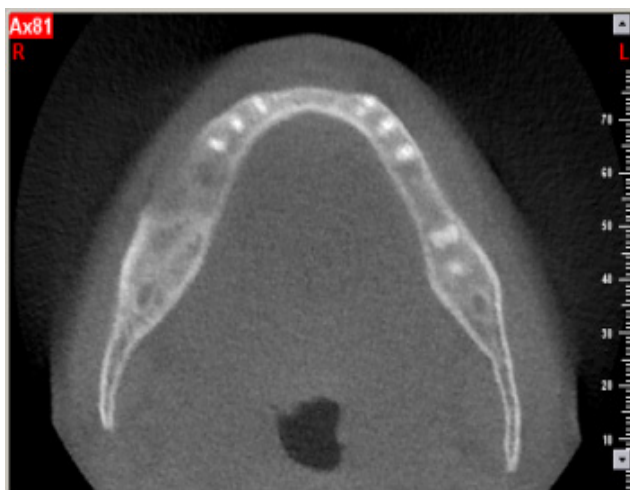Address for correspondence: mihaijuncar@gmail.com

### Method

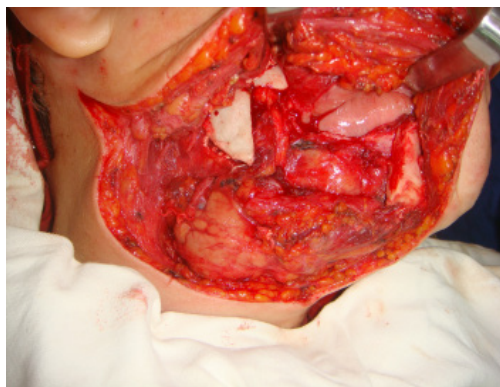
For the current research, four patients with mandibular tumors were selected. All patients signed an informed consent for surgery and participation in scientific studies. The selected patients were aged between 31 and 60 years, with a mean age of 41 years. Three of the selected patients were male. The clinical diagnosis of the patients included in the study was that of a tumor mass located



**Figure 1.** Panoramic radiograph evidencing the presence of an osteolysis area in the right horizontal mandibular ramus.



**Figure 2.** CT scan evidencing the presence of an osteolysis area in the right hemi-mandible, with cortical bone lysis toward the vestibular and lingual aspect.



**Figure 3.** Intraoperative appearance after tumor ablation.

in the mandible. Imaging investigations were performed for the determination of the location and extension of the tumor formations (Figures 1 and 2).

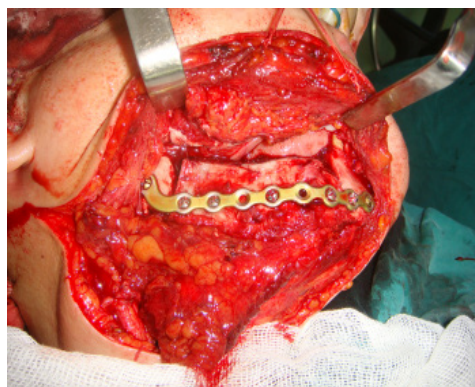
After incisional biopsy, samples were taken from the tumor; the diagnosis of squamous cell mucoepidermoid carcinoma was established in the case of two patients, the diagnosis of polycystic ameloblastoma was established in one patient, and that of myeloplax tumor in one patient.

After the histopathological diagnosis, surgery was performed and the tumor masses were resected within oncological safety limits. In all patients, segmental mandibular resection was conducted with the disruption of bone continuity and the removal of the tumor within oncological safety limits histologically confirmed (Figure 3). After tumor ablation, a vascularized iliac crest graft was taken for each case and was subsequently conformed to the bone defect. Then, the graft was fixed with an osteosynthesis titanium plate and screws, after which microsurgical anastomoses were performed (Figure 4).

Postoperative evolution was favorable, the patients were discharged after a mean hospitalization duration of 14 days, with a minimum of 11 days and a maximum of 18 days.

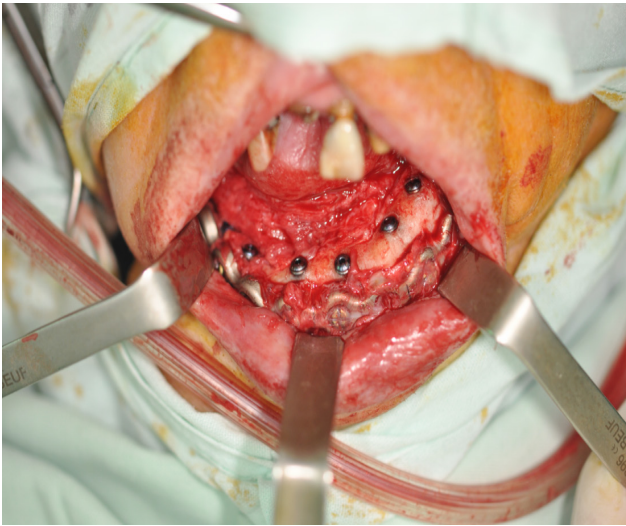
Postoperatively, all patients were monitored clinically and by imaging for the evolution of the bone grafts, as well as for the development of local or regional tumor recurrences. After a mean period of 154.75 days, with a minimum of 149 days and a maximum of 161 days, surgery was performed and dental implants were placed in the mandibular bone grafts for microsurgical reconstruction (Figure 5).

Postoperative evolution was favorable in the case of 3 of the 4 patients. In one patient, the fracture of the iliac crest graft occurred after the placement of implants. In this case, osteosynthesis with titanium plates and screws was performed, and subsequently, prosthetic rehabilitation treatment was continued (Figure 6).

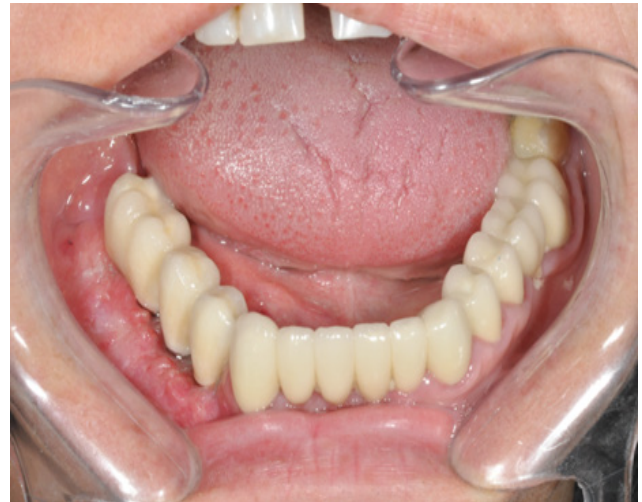

**Figure 4.** Intraoperative appearance after the placement of the iliac crest graft and its fixation with osteosynthesis plates.

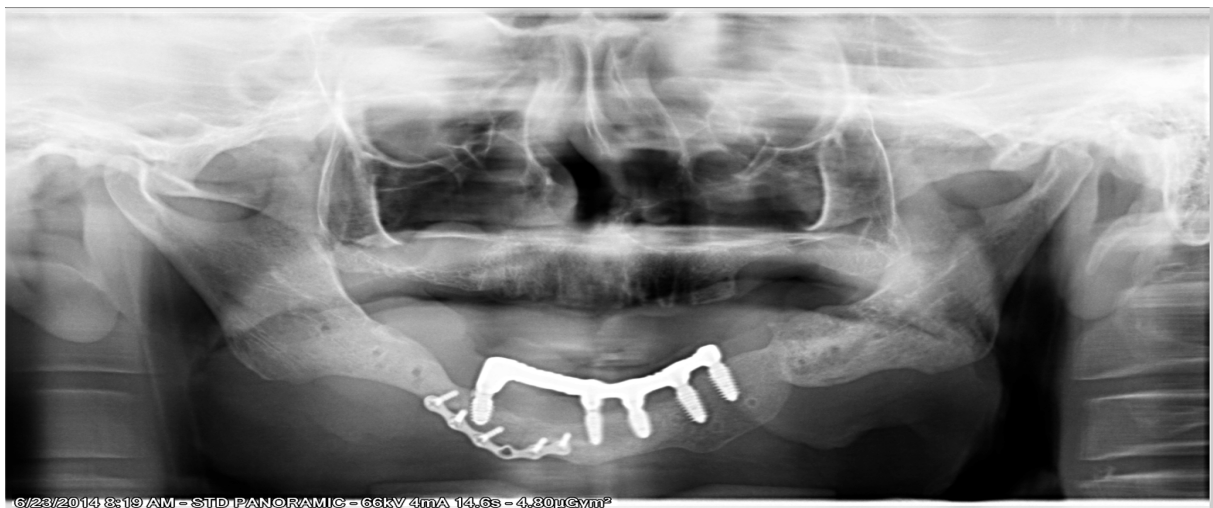



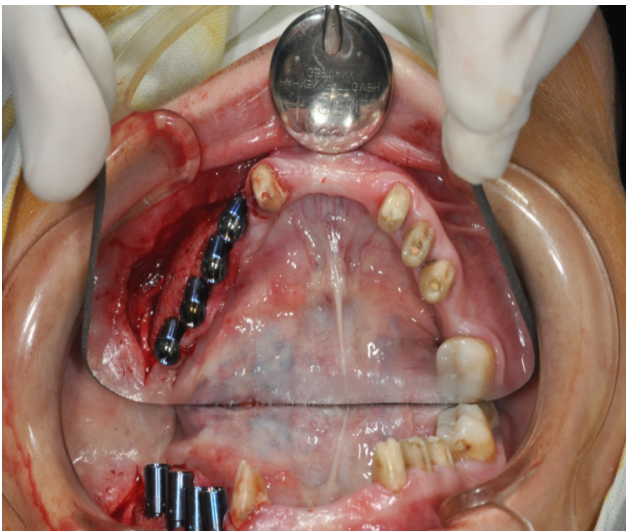
**Figure 5.** Clinical appearance after the placement of dental implants in the iliac crest grafts.



**Figure 8.** Clinical appearance after prosthetic reconstruction.



**Figure 6.** Imaging appearance of the fractured mandible after osteosynthesis and the application of the implant-supported prosthetic device.



**Figure 7.** Clinical appearance after the surgical exposure of dental implants for the placement of the prosthetic overstructure.

After the osseointegration of the dental implants was obtained, these were surgically exposed (Figure 7) and oral rehabilitation was performed using implant-supported prosthetic restorations in the case of three patients (Figure 8) and mixed support restoration in one patient.

The postoperative evolution of the patients was favorable, without being marked by subsequent complications or the development of local or regional recurrences. Patients were followed up for a period ranging between 6 months and 3 years, during which no pathological changes were found.

### Discussion

This study evaluated the possibility of mandibular reconstruction using vascularized iliac crest grafts. For the reconstruction of mandibular bone defects, several types of vascularized bone grafts have been used. Bone grafts

are most frequently taken from the iliac crest or the fibula. Either of them may have a number of advantages and disadvantages influencing the decision of the surgical team when making a choice. Previous studies seem to suggest the fact that iliac crest grafts allow for a better adaptation of the graft to the postoperative defect. Thus, in a study based on computer-assisted reconstruction planning, which assessed the adaptation of the two bone graft types to the receptor area, Ali Modabber et al. evidenced a higher degree of adaptation for iliac crest grafts [7]. It is obvious that the iliac crest graft also has a major disadvantage compared to a fibular graft, which is its short vascular pedicle [8]. Practitioners must consider this when selecting bone reconstruction methods and maintain an adequate length of vessels in the receptor area where vascular anastomoses are to be performed.

The great advantage of this type of vascularized grafts is the quality and the stability of the bone tissue used for mandibular reconstruction. Unlike non-vascularized grafts, vascularized grafts provide, as it can be seen, a bone structure that biologically manifests similarly to that of the bone structure in the receptor area. Mandibular dental implants are widely used, but their placement in non-vascularized grafts is avoided when bone continuity has been disrupted. On the other hand, the placement of dental implants in vascularized iliac crest grafts has a high success rate, reaching according to some authors 95.2% [9]. In the case of the patients included in this study, the osseointegration rate of dental implants was 100%, but it should not be overlooked that a limitation of the study is the small number of patients and implicitly, the relatively small number of implants used. However, the fact that no dental implant was lost suggests that this oral reconstruction and rehabilitation method is reliable and can be used on a wide scale.

Another limitation of this study is the short postoperative follow-up period. Literature studies monitoring the stability of dental implants placed in iliac crest grafts evidence a success rate between 91.8% and 96.4% 5 years after their placement, the difference between the two values being due to the type of implant placed [10].

These data correlated with the results obtained suggest the high degree of reliability of the current oral rehabilitation method.

## Conclusions

The oral rehabilitation of patients with segmental mandibular resections using vascularized iliac crest grafts and dental implants is a reliable option that can significantly improve the patients' quality of life.

## References

1. Ndukwe KC, Aregbesola SB, Ikem IC, Ugboko VI, Adebisi KE, Fatusi OA, et al. Reconstruction of mandibular defects using nonvascularized autogenous bone graft in nigerians. *Niger J Surg.* 2014;20(2):87-91.
2. Omeje K, Efunkoya A, Amole I, Akhiwu B, Osunde D. A two-year audit of non-vascularized iliac crest bone graft for mandibular reconstruction: technique, experience and challenges. *J Korean Assoc Oral Maxillofac Surg.* 2014;40:272-277.
3. Goh BT, Lee S, Tideman H, Stoelinga PJ. Mandibular reconstruction in adults: A review. *Int J Oral Maxillofac Surg.* 2008;37:597-605.
4. O'Brien CJ, Archer DJ, Breach NM, Shaw HJ. Reconstruction of the mandible with autogenous bone following treatment for squamous carcinoma. *Aust N Z J Surg.* 1986;56:707-715.
5. Cordeiro PG, Disa JJ, Hidalgo DA, Hu QY. Reconstruction of the mandible with osseous free flaps: a 10-year experience with 150 consecutive patients. *Plast Reconstr Surg.* 1999;104:1314-1320.
6. Disa JJ, Cordeiro PG. Mandible reconstruction with microvascular surgery. *Semin Surg Oncol.* 2000;19:226-234.
7. Modabber A, Ayoub N, Möhlhenrich SC, Goloborodko E, Sönmez TT, Ghassemi M, Loberg C, Lethaus B, Ghassemi A, Hölzle F. The accuracy of computer-assisted primary mandibular reconstruction with vascularized bone flaps: iliac crest bone flap versus osteomyocutaneous fibula flap. *Med Devices (Auckl).* 2014;7:211-217.
8. Brown JS, Jones DC, Summerwill A, Rogers SN, Howell RA, Cawood JJ, et al. Vascularized iliac crest with internal oblique muscle for immediate reconstruction after maxillectomy. *Br J Oral Maxillofac Surg.* 2002;40:183-190.
9. Navarro Cuellar C, Caicoya SJ, Acero Sanz JJ, Navarro Cuellar I, Muela CM, Navarro Vila C. Mandibular reconstruction with iliac crest free flap, nasolabial flap, and osseointegrated implants. *J Oral Maxillofac Surg.* 2014;72(6):1226.e1-15.
10. Zou D, Huang W, Wang F, Wang S, Zhang Z, Zhang C, et al. Autologous Ilium Grafts: Long-term results on immediate or staged functional rehabilitation of mandibular segmental defects using dental implants after tumor resection. *Clin Implant Dent Relat Res.* 2013 Oct 31. doi: 10.1111/cid.12169. [Epub ahead of print].